

Digestive System of Goats

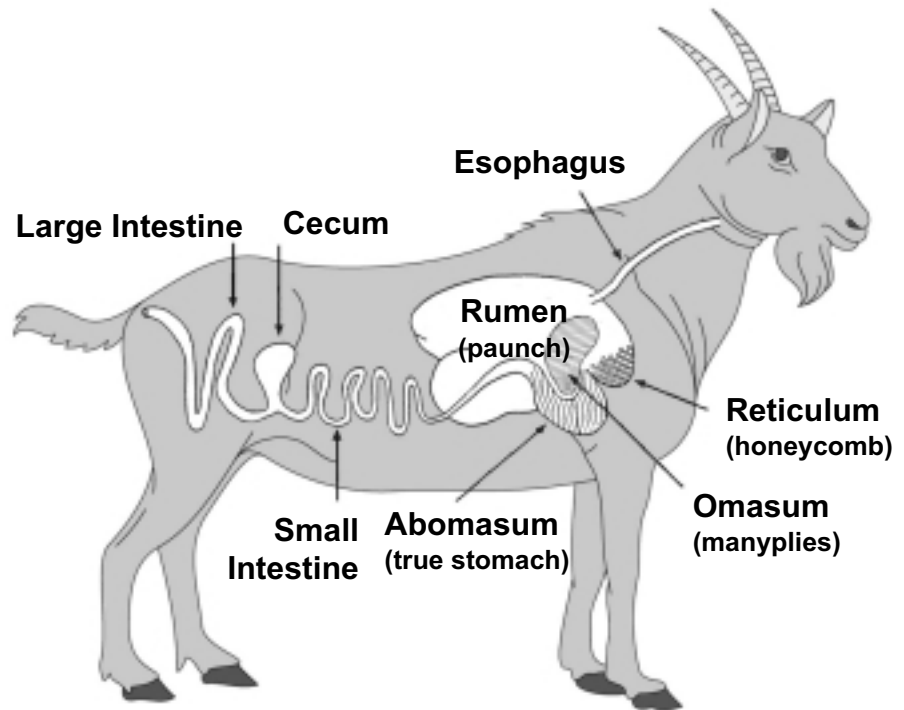
Introduction

Mature goats are herbivorous ruminant animals. Their digestive tracts, which are similar to those of cattle, sheep, deer, elk, bison, and giraffes, consist of the mouth, esophagus, four stomach compartments, small intestine, cecum, and large intestine. A brief description of the anatomy and physiology of the mouth and the stomach compartments of goats follows.

Mouth: Like other ruminant animals, goats have no upper incisor or canine teeth. They depend on the rigid dental pad in front of the hard palate, the lower incisor teeth, the lips, and the tongue to take food into their mouths.

Esophagus: This is a tubelike passage from the mouth to the stomach. The esophagus, which opens into the stomach at the junction of the rumen and reticulum, helps transport both gases and cud.

Rumen: This is the largest of the four stomach compartments of ruminant animals. The capacity of the rumen of goats ranges from 3 to 6 gallons



The digestive tract of goats.

depending on the type of feed. It is lined with small fingerlike projections called papillae, which increase the absorptive surface of the rumen. This compartment, also known as the paunch, contains many microorganisms, such as bacteria and protozoa, that supply enzymes to break down fiber and other feed parts. Microbiological activities in the rumen result in the conversion of the starch and fiber of feeds to the volatile fatty acids acetic, propionic, and butyric acids. These volatile fatty acids are

absorbed through the rumen wall and provide as much as 80 percent of the animal's total energy requirements. Microbial digestion in the rumen is the reason that ruminant animals effectively use fibrous feeds and are maintained primarily on roughages.

Rumen microorganisms also convert components of the feed to useful products such as essential amino acids, B-complex vitamins, and vitamin K. Afterward, the microorganisms themselves are

digested in the small intestine to free up these nutrients for the ruminant animal's use.

In the process of digesting feeds, rumen microorganisms also produce large amounts of gases, primarily methane and carbon dioxide. The animal normally eliminates these gases by eructation (belching). When the gases are produced faster than the animal can eliminate them, a potentially lethal condition known as bloat can result. This condition is often associated with the rapid consumption of large amounts of leguminous vegetation.

Reticulum: This compartment, also known as the honeycomb or hardware stomach, is located just below the entrance of the esophagus into the stomach. When goats swallow foreign objects such as wire, nails, and screws, these objects can become lodged in the reticulum, potentially causing serious injury. The reticulum is part of the rumen separated only by an overflow connection, the rumino-reticular fold.

Therefore, microbial action also takes place in this compartment. The capacity of the reticulum of goats ranges from 1/4 to 1/2 gallon.

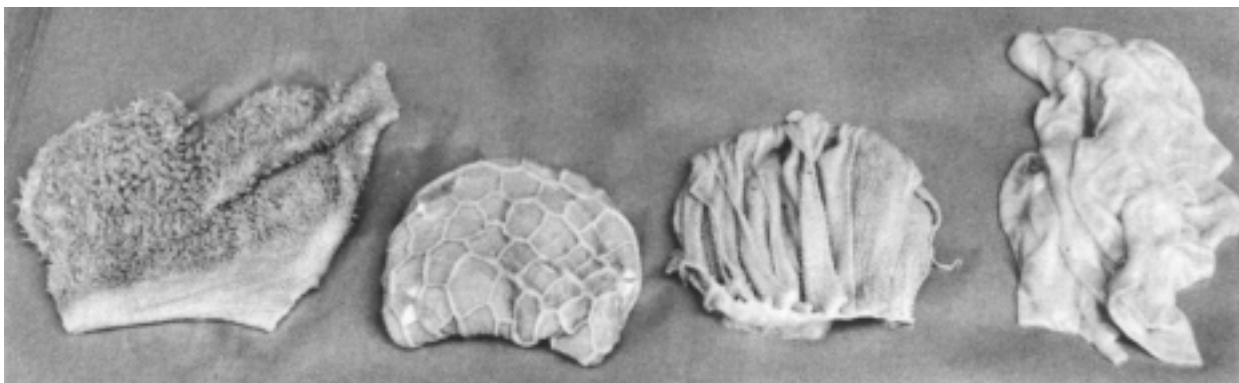
Omasum: This compartment, also known as the manyplies, consists of many folds or layers of tissue that grind up feed ingesta and squeeze some of the water from the feed. The capacity of the omasum of goats is approximately 1/4 gallon.

Abomasum: This compartment is often considered the true stomach of ruminant animals. It functions similarly to human stomachs. The mucosa of the fundus contains parietal cells, which secrete hydrochloric acid, and chief cells, which secrete the enzyme pepsin. This enzyme is secreted in an inactive form (pepsinogen), which is then activated by hydrochloric acid. Pepsin is responsible for breaking down feed proteins before they enter the small intestine. The pylorus, which is the terminal portion of the abomasum, is characterized by secretions that are largely

mucous. The capacity of the abomasum of goats is approximately 1 gallon.

Small Intestine: As partially digested feed enters the duodenum, the first part of the small intestine, the enzymes produced and secreted by the pancreas and the Brunner's glands of the duodenum further break down feed nutrients into simple compounds. These compounds are absorbed into the bloodstream or lymph by an active process carried on largely in the jejunum and ileum (second and third part of the small intestine, respectively). The small intestinal wall is lined with many small fingerlike projections called villi, which increase the absorption area of the small intestine. The capacity of the small intestine of goats is approximately 2-1/2 gallons.

Cecum: This simple tubular structure, also known as the blind gut, is located at the junction of the small and large intestines. Feed materials entering this compartment are digested by



Inside structures of rumen, reticulum, omasum, and abomasum of goats. Photo courtesy of G. F. W. Haenlein, University of Delaware.

inhabiting microorganisms. The capacity of the cecum of goats is approximately 1/4 gallon.

Large Intestine: Undigested feed and unabsorbed nutrients leaving the small intestine pass into this compartment. The functions of the large intestine include water absorption and further digestion of feed materials by microorganisms. The large intestine is comprised of the colon and rectum. Fecal pellets are formed in the end portion of the spiral colon. The capacity of the large intestine of goats ranges from 1-1/4 to 1-1/2 gallons.

Accessory Glands: The salivary glands, liver, and pancreas contribute to digestion. Saliva secreted by the salivary glands is important in the chewing of the cud. Bile produced by the liver, and stored and secreted by the gall bladder, helps emulsify fat in preparation for digestion. Enzymes secreted by the pancreas are important in the small intestinal digestion of carbohydrates, proteins, and fats.

Development of the Four Stomach Compartments

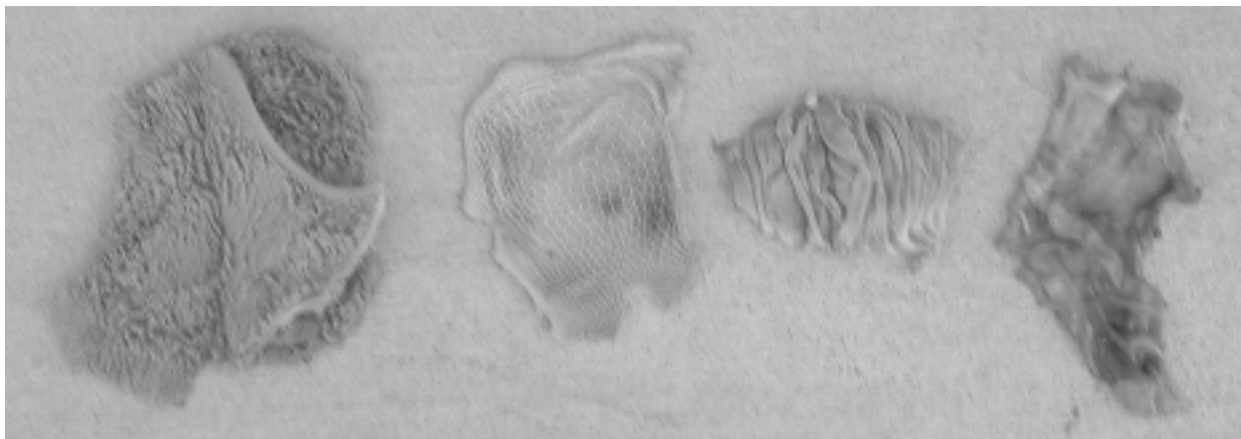
When a goat kid is born, the rumen is small and the abomasum is the largest of the four stomach compartments. The rumen of a goat kid is about 30 percent of the total stomach area, while the abomasum is about 70 percent. Hence, digestion in the goat kid is like that of a monogastric animal. In the suckling goat kid, closure of the esophageal groove ensures that milk is channeled directly to the abomasum instead of going through the rumen, reticulum, and omasum. Peptic cells in the abomasum of young milk-fed ruminants secrete, in addition to pepsin, the enzyme rennin. This enzyme is responsible for forming milk curdles and digesting milk protein.

When the suckling goat kid starts to eat vegetation during the first or second week after birth, the rumen, reticulum, and omasum gradually develop in size and

function. After approximately two months, the four stomach compartments reach their relative adult proportions.

Rumination

Rumination is defined as the regurgitation, rechewing, and reswallowing of rumen ingesta. During resting, animals with four stomach compartments regurgitate ball-like masses of fibrous and coarse feeds called bolus or the cud. The regurgitated cud is chewed thoroughly for about one minute then swallowed again. Ruminant animals may spend up to 8 hours per day in rumination, depending on the type of feed. This phenomenon affects the amount of feed the goat can eat. Reducing the particle size of the feed through rechewing allows the material to be easily accessible to the microorganisms and to pass out of the rumen.




Inside structures of rumen, reticulum, omasum, and abomasum of deer. Photo courtesy of G. F. W. Haenlein, University of Delaware.

Summary

Digestion in ruminant animals is accomplished via microbial breakdown of feed parts in the rumen and reticulum, enzymatic activity in the abomasum and small intestine, and microbial breakdown in the cecum and large intestine. The simple compounds derived from the digestion of carbohydrates, proteins, and fats are absorbed mainly from the forestomach and small intestine.

References

- Church, D. C. (1993). *The ruminant animal: Digestive physiology and nutrition*. Prospect Heights, IL: Waveland Press, Inc.
- Ensminger, M. E. (2002). *Sheep and goat science*. 6th ed. Danville, IL: Interstate Publishers, Inc.
- Gillespie, J. R. (1998). *Animal science*. Albany, NY: Delmar Publishers.
- Jurgens, M. H. (1993). *Animal feeding and nutrition*. 7th ed. Dubuque, IA: Kendall/Hunt Publishing Company.
- Randall, D., Burggren, W., & French, K. (2002). *Eckert animal physiology: Mechanisms and adaptations*. 5th ed. New York, NY: W.H. Freeman and Company.
- Shapiro, L. S. (2001). *Introduction to animal science*. Upper Saddle River, NJ: Prentice-Hall, Inc.
- Taylor, R. E. and T. G. Field. (2001). *Scientific farm animal production: An introduction to animal science*. 7th ed. Upper Saddle River, NJ: Prentice-Hall, Inc.



Your Experts for Life

UNP-60

Julio E. Correa, Associate Professor and Extension Animal Scientist, Alabama A&M University

Special thanks to **Jean Hall Dwyer**, *Extension Communications Specialist*, for the drawing "The digestive tract of goats."

For more information, call your county Extension office. Look in your telephone directory under your county's name to find the number.

Issued in furtherance of Cooperative Extension work, Acts of May 8 and June 30, 1914, in cooperation with the U.S. Department of Agriculture, by the Alabama Cooperative Extension System (Alabama A&M University and Auburn University).

New August 2007; UNP-60

© 2007 by Alabama Cooperative Extension System. All rights reserved.